

CASE REPORT

THALAMIC INFARCTION FOLLOWING A RUSSELL'S VIPER BITE

Abraham M Ittyachen and Mohan B Jose

Department of Medicine, Malankara Orthodox Syrian Church Medical College, Kolenchery, Kerala State, India

Abstract. We report a case of a Russell's viper (*Daboia russelii*) bite involving a 55-year-old male who developed a bilateral thalamic infarction. Although the coagulopathy was controlled within twenty-four hours, the patient became restless and disoriented. Due to the initial prolonged clotting time, we suspected an intracranial bleed. T2 magnetic resonance imaging (MRI) of the brain showed bilateral infarcts of the thalamus. Cerebral infarction secondary to snake envenomation has been reported before, but to our knowledge bilateral involvement of the thalamus has not been reported.

Keywords: snake envenomation, thalamic infarction

INTRODUCTION

Snake bites are common throughout the world, but the burden is higher in developing countries; there is a higher mortality due to lack of timely, appropriate medical care, not to mention the cost and loss of productivity. Globally, at least 421,000 envenomations and 20,000 deaths occur yearly due to snakebite (Kasturiratne *et al*, 2008). India has the greatest number of annual envenomations and deaths: 81,000 and 11,000, respectively (Kasturiratne *et al*, 2008). A recent study from India suggests the death rate in India may be even higher (Mohapatra *et al*, 2011). There are 4 main deadly species

of snake in India: spectacled cobra (*Naja naja*), common krait (*Bungarus caeruleus*), saw-scaled viper (*Echis carinatus*) and Russell's viper (*Daboia russelii*), but other species may cause fatal snakebites in specific areas (Simpson and Norris, 2007), such as the hump-nosed pit-viper (*Hypnale hypnale*) which has been described in this part of India (Simpson and Norris, 2007; Mohapatra *et al*, 2011).

Kolenchery is a small village situated in the state of Kerala in southern India. The climate is warm and humid and agriculture is the chief occupation, with the main products being rice, rubber, spices and pineapple. These factors also contribute to the deadly interaction between man and snake. We describe here an unusual complication of a Russell's viper bite.

Correspondence: Prof Abraham M Ittyachen, Malankara Orthodox Syrian Church Medical College, Kolenchery-682311, Ernakulam District, Kerala State, India.

Tel: +91 484 3055555; Fax: +91 484 2760409

E-mail: abyiliz@rediffmail.com

CASE REPORT

A 55-year-old otherwise healthy man



Fig 1—The brought-in Russell's viper (*Daboia russelii*).

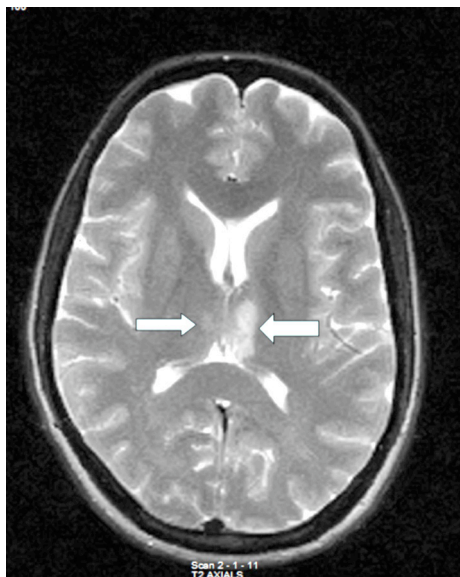


Fig 2—T2 magnetic resonance imaging (MRI) of the brain showing bilateral thalamic infarcts.

was brought to the emergency department of our hospital with a history of snake bite. He was working in the fields when the incident occurred and was brought in within one hour of the incident. As is the usual practice in this region, the snake was killed and brought in for identification. Though partly soiled, the specimen

could be identified as a large Russell's viper (*Daboia russelii*) (Fig 1).

The patient was restless and disoriented on admission but the rest of the neurological examination was normal. The patient had two deep fang marks on the left big toe, but there was no significant local reaction. The initial clotting time was more than one hour. After a test dose, he was given a loading dose of ten vials of equine polyvalent antivenom (ASV) in the emergency department and tetanus toxoid. The wound was covered with an alcohol based dressing, the patient was started on parenteral ampicillin and metronidazole and admitted to the intensive care unit.

Over the next eight hours the patient received twelve more vials of ASV via infusion pump while monitoring the coagulation profile. Eight hours into treatment, the clotting time had normalized, but the clot again lysed and began bleeding within ten minutes; he was given four more vials of ASV. The patient did not require inotropic medication during hospitalization. The initial hemogram, renal and hepatic function tests were normal. The patient developed no undesirable reactions, immediate or delayed, to the antivenom.

The following morning the patient continued to be hemodynamically stable. Coagulation studies were also within normal limits, but the patient continued to be drowsy. The disorientation, restlessness and prolonged clotting time caused us to suspect an intracranial bleed. T2 magnetic resonance imaging (MRI) of the brain revealed bilateral thalamic infarcts (Fig 2).

There was a steady improvement in the sensorium of the patient. A gradual drop in the platelet count was noted until the fifth day of hospitalization (75,000

cells/mm³), after which the count returned to normal by the seventh day of hospitalization. The patient was discharged on the tenth day of hospitalization, conscious, fully oriented with no residual neurological deficits. He was followed up as an out-patient for the next six months and continued to be healthy.

DISCUSSION

This patient had bilateral thalamic infarction secondary to a viper bite. To our knowledge this is the first case of snake envenomation responsible for bilateral thalamic infarction. Cases of infarction involving the central nervous system secondary to viper bites have been reported before. Bashir and Jenkins (1985) reported a 13-year-old girl was bitten on the hand by a viper, with complications of hemiplegia and aphasia. Narang *et al* (2009) reported an 18-year old male who developed right hemiplegia with expressive aphasia following a Russell's viper bite. Merle *et al* (2005) reported a patient with occipital infarction due to snake bite. Several cases of cerebral secondary to *Bothrops caribbaeus* and *Bothrops lanceolatus* bites have been reported from Martinique, French West Indies (Thomas *et al*, 1995; Numeric *et al*, 2002).

The exact mechanism for the thrombotic complications remains unknown. In our patient, ASV was administered within one hour of the incident. Coagulopathy was controlled within twenty four hours; however, the patient still developed a thalamic infarction.

Several mechanisms have been postulated. Bogarin *et al* (1999) found the addition of *B. lanceolatus* venom to human plasma with citrate, did not cause coagulation, even at high concentrations. This suggests other factors, such as an

alteration in the vascular wall, causing adhesions and aggregation of platelets, may be a contributing factor to thrombosis. Other possible mechanisms include intravascular coagulation with small and large vessel occlusion (Schwartman and Hill, 1982), toxic vasculitis, severe vascular spasm and hypercoagulation secondary to procoagulant in the venom (Bashir and Jenkins, 1985).

Physicians working in tropical countries should be aware of this rare complication of viper envenomation and the fact that antsnake venom may have no effect on the prevention of this complication. Further research on the effects of viper venom are needed, including the role of mediators and methods to prevent thrombotic complications.

REFERENCES

- Bashir R, Jenkins J. Cerebral infarction in a young female following snake bite. *Stroke* 1985; 16: 328-30.
- Bogarin G, Romero M, Rojas G, *et al*. Neutralization by a monospecific *Bothrops lanceolatus* antivenom, of toxic activities induced by homologous and heterologous *Bothrops* snake venoms. *Toxicon* 1999; 37: 551-7.
- Kasturiratne A, Wickremasinghe AR, de Silva N, *et al*. The global burden of snakebite: a literature analysis and modelling based on regional estimates of envenoming and deaths. *PLoS Med* 2008; 5: e218.
- Merle H, Donnio A, Ayeboua L, Plumelle Y, Smadja D, Thomas L. Occipital infarction revealed by quadrantanopsia following snakebite by *Bothrops lanceolatus*. *Am J Trop Med Hyg* 2005; 73: 583-5.
- Mohapatra B, Warrell DA, Suraweera W, *et al*. Snakebite mortality in India: a nationally representative mortality survey. *PLoS Negl Trop Dis* 2011; 5: e1018.
- Narang SK, Paleti S, Azeez Asad MA, Samina T. Acute ischemic infarct in the middle

- cerebral artery territory following a Russell's viper bite. *Neurol India* 2009; 57: 479-80.
- Numeric P, Moravie V, Didier M, *et al.* Multiple cerebral infarctions following a snakebite by *Bothrops caribbaeus*. *Am J Trop Med Hyg* 2002; 67: 287-8.
- Schwartzman RJ, Hill JB. Neurologic complications of disseminated intravascular coagulation. *Neurology* 1982; 32: 791-7.
- Simpson ID, Norris RL. Snakes of medical importance in India: is the concept of the "Big 4" still relevant and useful? *Wilderness Environ Med* 2007; 18: 2-9.
- Thomas L, Tyburn B, Bucher B, *et al.* Prevention of thromboses in human patients with *Bothrops lanceolatus* envenoming in Martinique: failure of anticoagulants and efficacy of a monospecific antivenom. *Am J Trop Med Hyg* 1995; 5: 419-26.